SHO TRAUMA SERIES

ANKLE FRACTURES

MR MJ WELCK

CONSULTANT ORTHOPAEDIC FOOT AND ANKLE SURGEON

CONTENTS

- DEFINITION
- EPIDEMIOLOGY
- ANATOMY
- CLASSIFICATION
- DIAGNOSIS
- INDICATIONS FOR SURGERY
- SURGERY
- REHAB
- CASE

DEFINITION

- FRACTURE INVOLVING THE MALLEOLI

EPIDEMIOLOGY

- 100 PER 100,000
- YOUNGER (MEN)
- OLDER (WOMEN)
- ISOLATED LM 70%

ANATOMY

- Talocrural angle
  - 8-15 o.
  - Smaller is
  - fibular shortening.

Normal talocrural angle

Small talocrural angle

ANATOMY

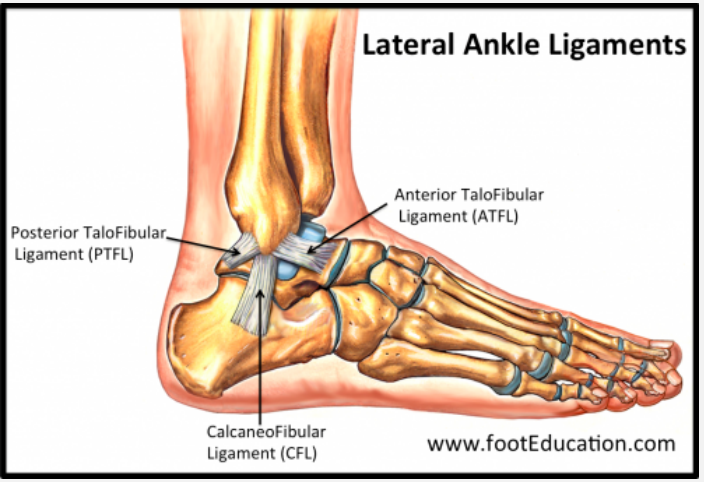
Lateral Ankle Ligaments
Anterior TaloFibular Ligament (ATFL)
Posterior TaloFibular Ligament (PTFL)
CalcaneoFibular Ligament (CFL)
www.footEducation.com

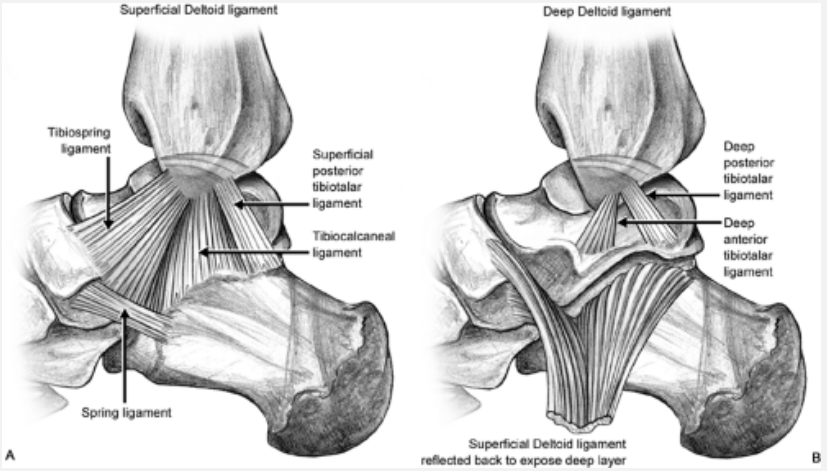
Superficial Deltoid ligament
Tibiospring ligament
Superficial posterior tibiotalar ligament
Tibiocalcaneal ligament
Spring ligament
A
Deep Deltoid ligament
Deep posterior tibiotalar ligament
Deep anterior tibiotalar ligament
Superficial Deltoid ligament reflected back to expose deep layer
B

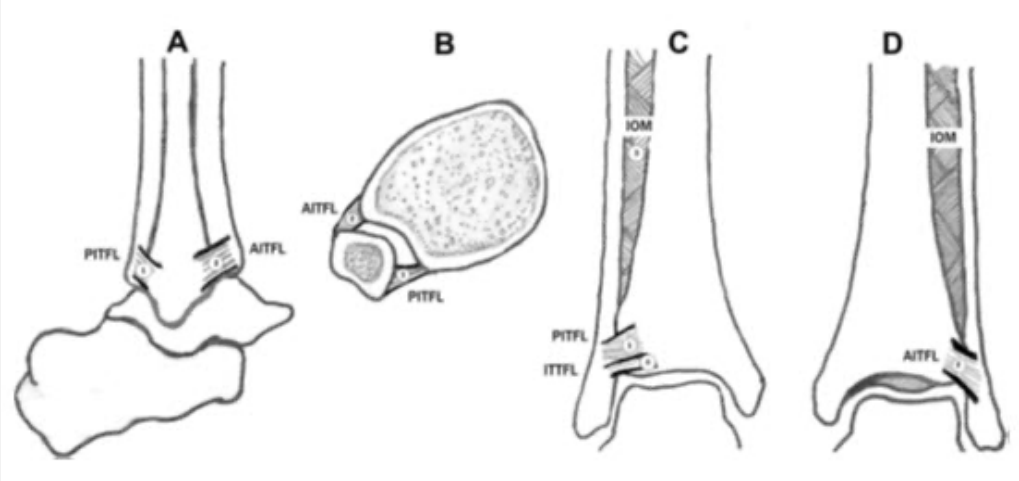
A
B
C
D
PITFL
AITFL
AITFL
PITFL
IOM
PITFL
ITTFL
IOM
AITFL

CLASSIFICATION

DANIS-WEBER

- LEVEL OF FIBULA FRACTURE
- INCREASING INSTABILITY
- SIMPLE

LAUGE HANSEN

- MECHANISTIC
- MORE COMPLEX BUT SIMPLE

AO

- HARD TO REMEMBER!

WEBER

Weber classification

- Level of fibular fracture relative to the syndesmosis
- A = below syndesmosis
- B = level of syndesmosis
- C = above level of syndesmosis

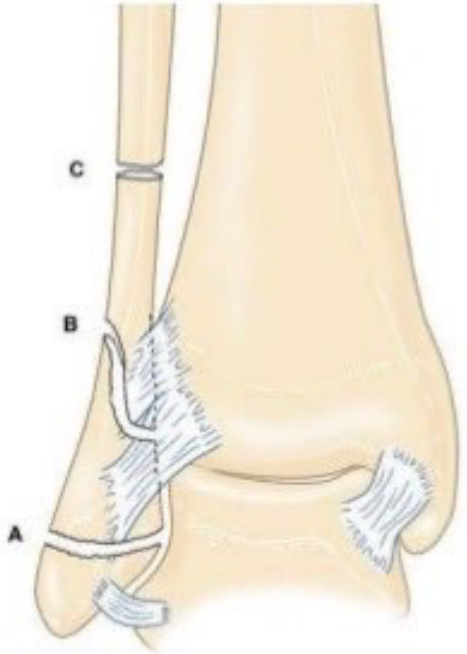

LAUGE HANSEN

- POSITION OF FOOT
  - SUPINATION OR PRONATION
- FORCE THAT HAPPENS TO TALUS

  - = SUPINATION EXT ROT, SUPINATION ADDUCTION
  - = PRONATION EXT ROTATION, PRONATION ABDUCTION

CLOCKWISE

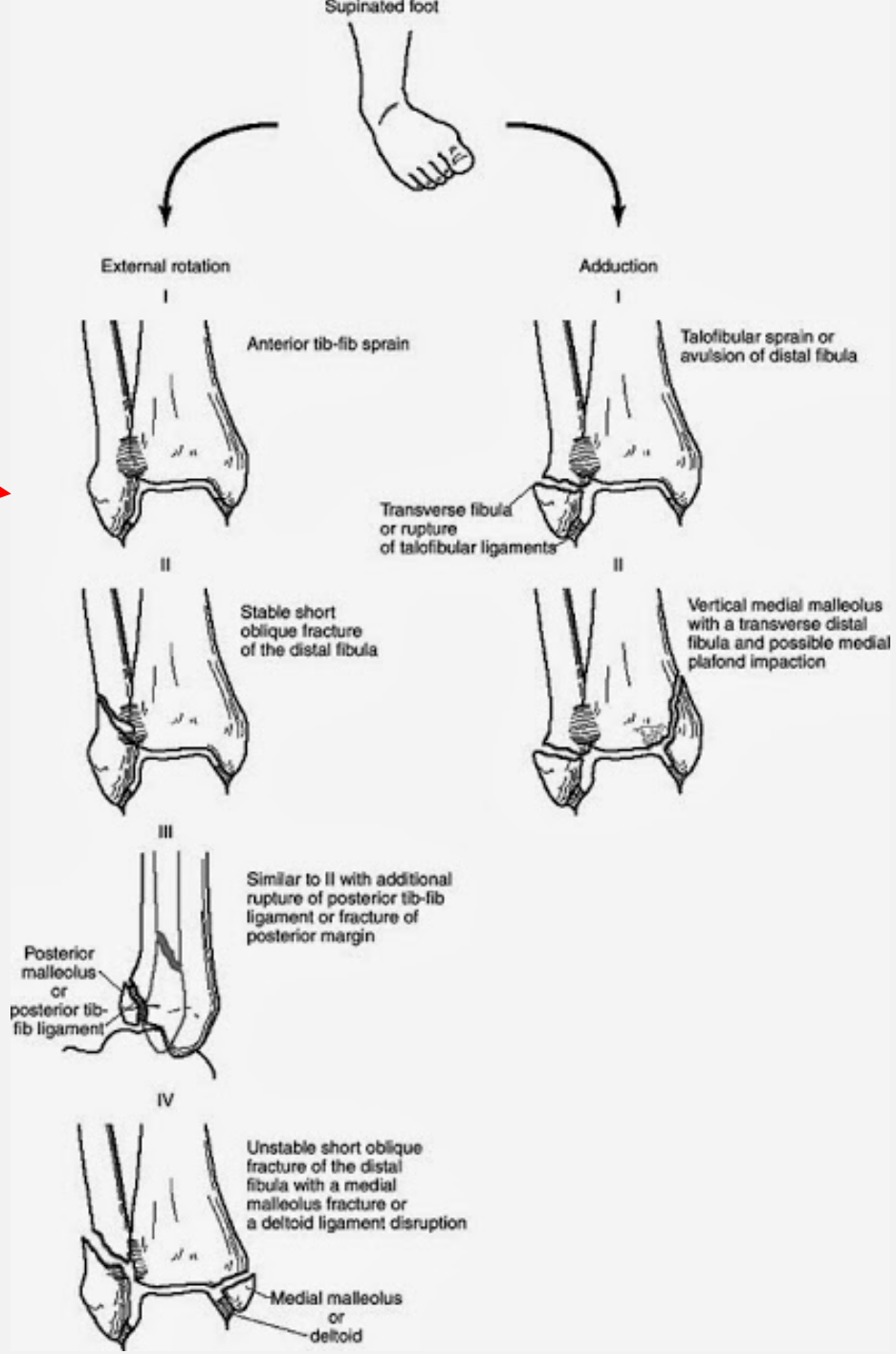
Supinated foot
External rotation
I
Anterior tib-fib sprain
II
Stable short oblique fracture of the distal fibula
III
Similar to II with additional rupture of posterior tib-fib ligament or fracture of posterior margin
Posterior malleolus or posterior tib-fib ligament
IV
Unstable short oblique fracture of the distal fibula with a medial malleolus fracture or a deltoid ligament disruption
Medial malleolus or deltoid
Adduction
I
Talofibular sprain or avulsion of distal fibula
Transverse fibula or rupture of talofibular ligaments
II
Vertical medial malleolus with a transverse distal fibula and possible medial plafond impaction

CLOCKWISE

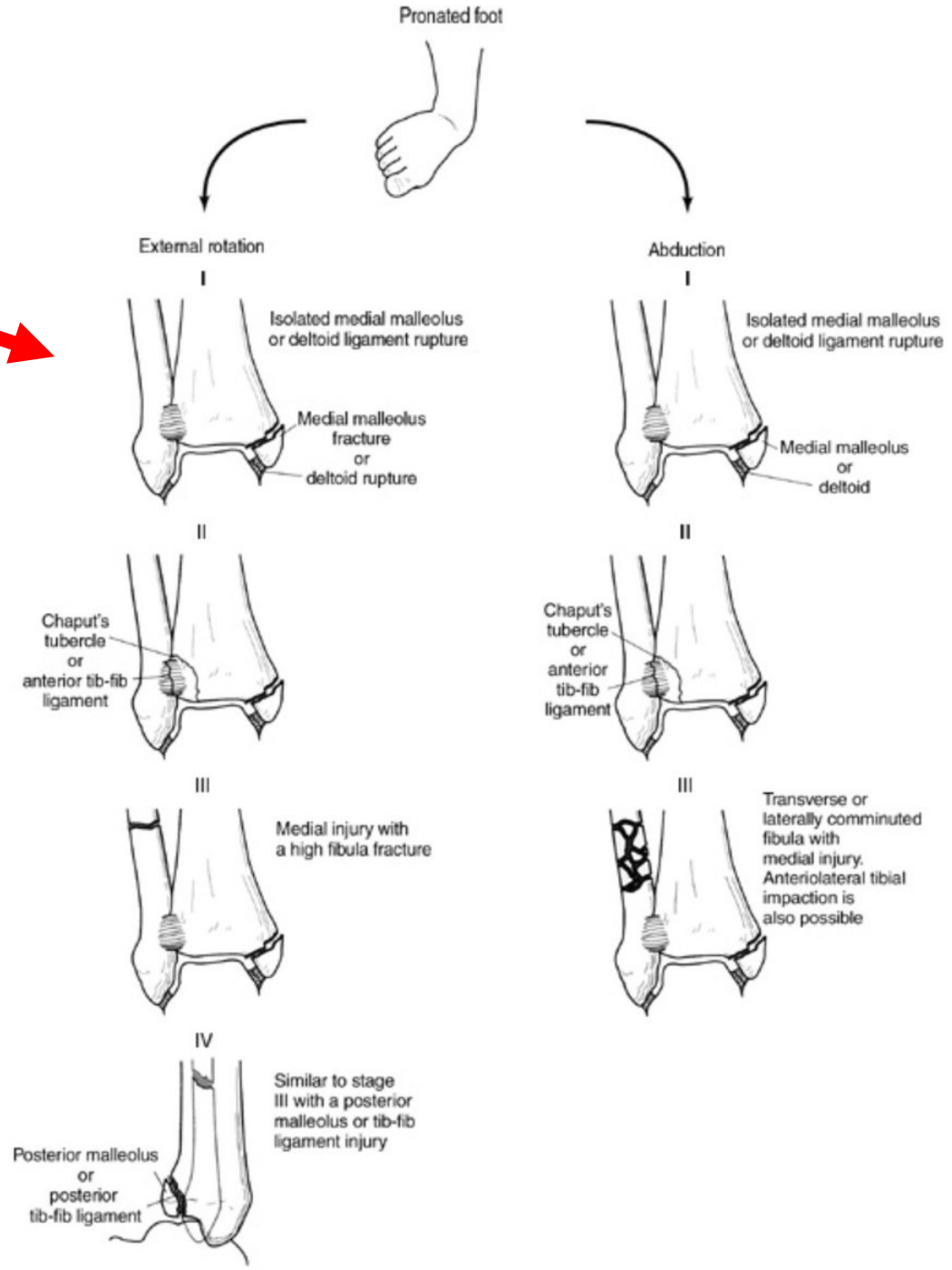
Pronated foot
External rotation
I
Isolated medial malleolus or deltoid ligament rupture
Medial malleolus fracture or deltoid rupture
II
Chaput's tubercle or anterior tib-fib ligament
III
Medial injury with a high fibula fracture
IV
Similar to stage III with a posterior malleolus or tib-fib ligament injury
Posterior malleolus or posterior tib-fib ligament
Abduction
I
Isolated medial malleolus or deltoid ligament rupture
Medial malleolus or deltoid
II
Chaput's tubercle or anterior tib-fib ligament
III
Transverse or laterally comminuted fibula with medial injury. Anteriolateral tibial impaction is also possible

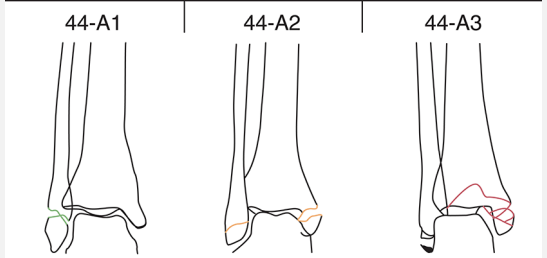

44-A infrasyndesmotic lesion

44-A1 isolated
44-A2 with fractured medial malleolus
43-A3 with posteromedial fracture

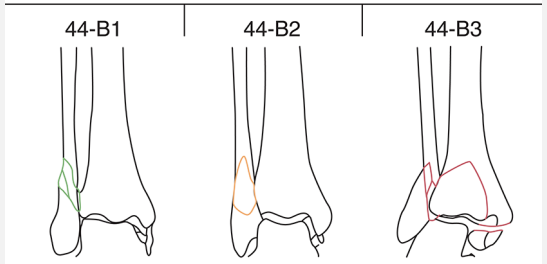

44-B transsyndesmotic fibular fracture

44-B1 isolated
44-B2 with medial lesion
44-B3 with medial lesion and Volkmann's fracture

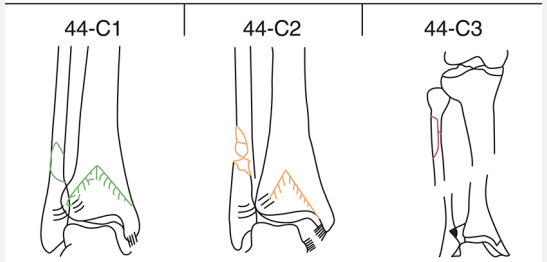

44-C suprasyndesmotic lesion

44-C1 fibular diaphyseal fracture, simple
44-C2 fibular diaphyseal fracture, multifragmentary
44-C3 proximal fibular lesion

DIAGNOSIS

- CLINICAL
- MEDIAL BRUISING
- BRUISING PAIN UP SYNDESMOSIS
- KNEE
- SWELLING
- NV
- OTTOWA ANKLE RULES

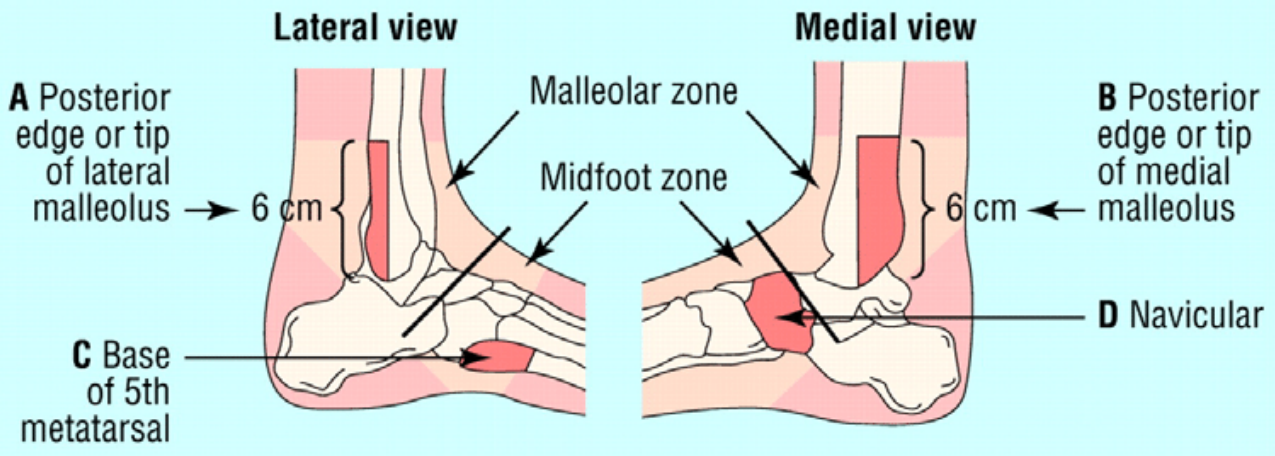

An ankle x ray series is required only if there is any pain in malleolar zone and any of these findings:
- Bone tenderness at **A**
- Bone tenderness at **B**
- Inability to bear weight both immediately and in emergency department

A foot x ray series is required only if there is any pain in midfoot zone and any of these findings:
- Bone tenderness at **C**
- Bone tenderness at **D**
- Inability to bear weight both immediately and in emergency department

IMAGING

AP, MORTICE, LATERAL ANKLE
CONSIDER AP KNEE

OFTEN NWB.	WB USEFUL	CHECK NOT IN EQUINUS

LOOK AT LATERAL MALL, MEDIAL MALL AND DLETOID, SYNDESMOSIS

▪XRAY

TIBIOFIBULAR OVERLAP (1cm. 6MM VS 1MM),
TIBIOFIBULAR CLEAR SPACE (1cm. 6MM),
MEDIAL CLEAR SPACE (mortice, 4.5MM),

✓ WEIGHT BEARING

× POOR REPRODUCIBILITY,
ROTATION DEPENDENT,
MAGNIFICATION DEPENDENT
POOR SENSITIVITY FOR SUBTLE,
WIDE VARIATION OF NORMAL

AP VIEW 48% SENS, MORTICE 64%

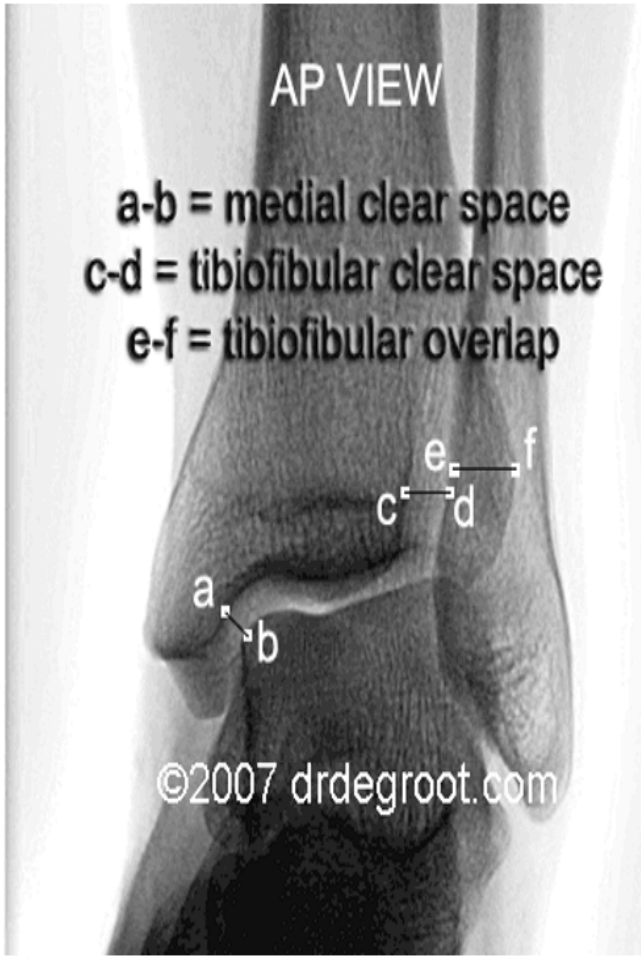

POSTERIOR MALLEOLUS

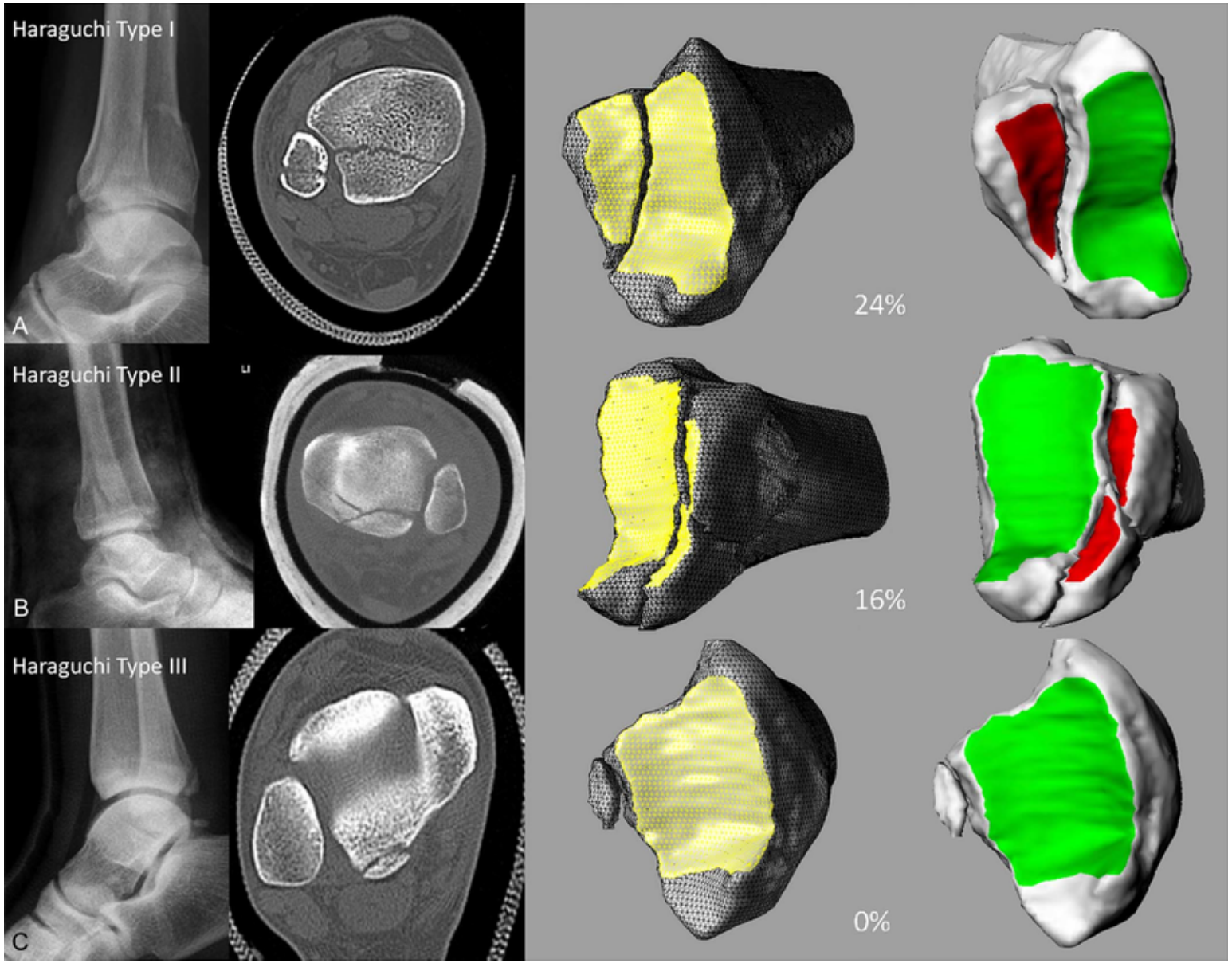

INDICATIONS FOR SURGERY

UNSTABLE FRACTURE

- MEDIAL AND LATERAL SIDES GONE
- LATERAL AND SYNDESMOSIS
- 'RING'

DISPLACED FRACTURE

- FIBULA SHORTENED, ROTATED.
- 3MM DISPLACEMENT FIBULA FRACTURE

STABILITY

SO ISOLATED, UNDISPLACED LATERAL OR MEDIAL MALL FRACTURE DON'T NEED FIXING… THEY ARE STABLE

BUT WHAT IF FIBULAR FRACTURE AND DELTOUID INJURY??

- IF EQUIVOCAL, EG BRUISING MEDIALLY, NO WIDENING, SUGGEST WB XRAY AT 1 WEEK

SURGERY

- FIBULA
  - STANDARD IS 3.5MM LAG SCREW + 1/3 TUBULAR NEUTRALISATION PLATE
    - MINUMUM 2 SCREWS PROX AND DISTAL
  - IF VERY DISTAL MAY NEED LOCKING PLATE
  - IF CANT LAG, NEED STRONGER PLATE.
  - FIX IF WITHIN 7CM OF MORTICE

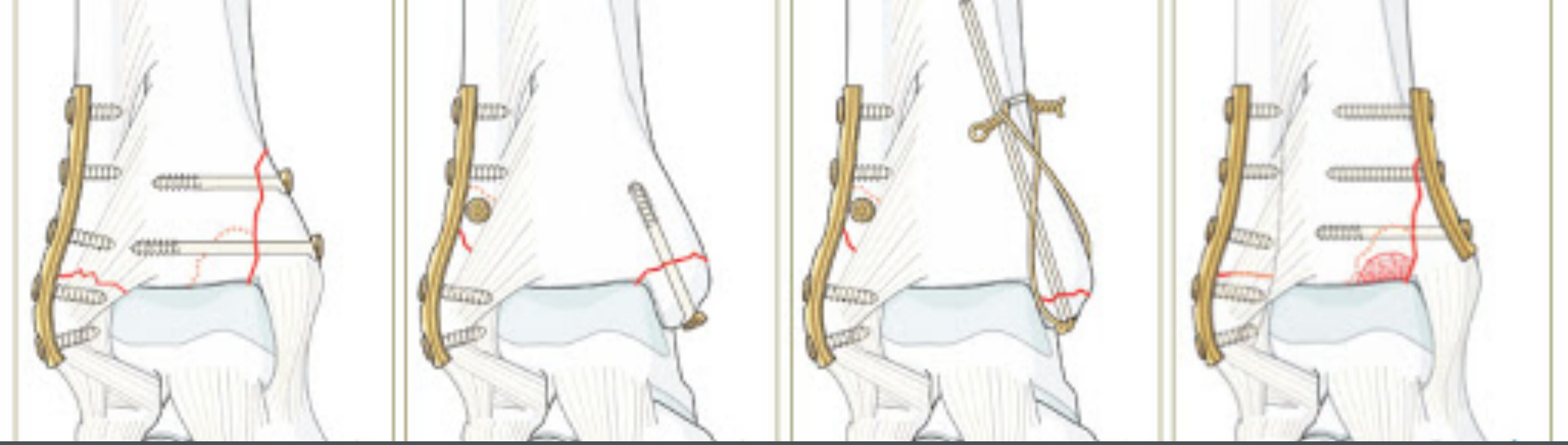

MEDIAL SIDE

- 2 LAG SCREWS
  - 3.5 OR 4 MM +/- WASHER
- TBW
- ANTIGLIDE PLATE FOR VERTICAL FRACTURES
- DELTOID REPAIR FOR LIGAMENT INJURY CONTROVERSIAL

SYNDESMOSIS

- ALWAYS TEST WITH BONE HOOK UNDER II
- WITHIN 2-3 CM OF PLAFOND
- 3.5MM OR 4.5MM SCREWS
- 1 OR 2
- 3 OR 4 CORTICES
- REMOVE OR NOT (NOT BEFORE 3/12)
- TIGHTROPE.

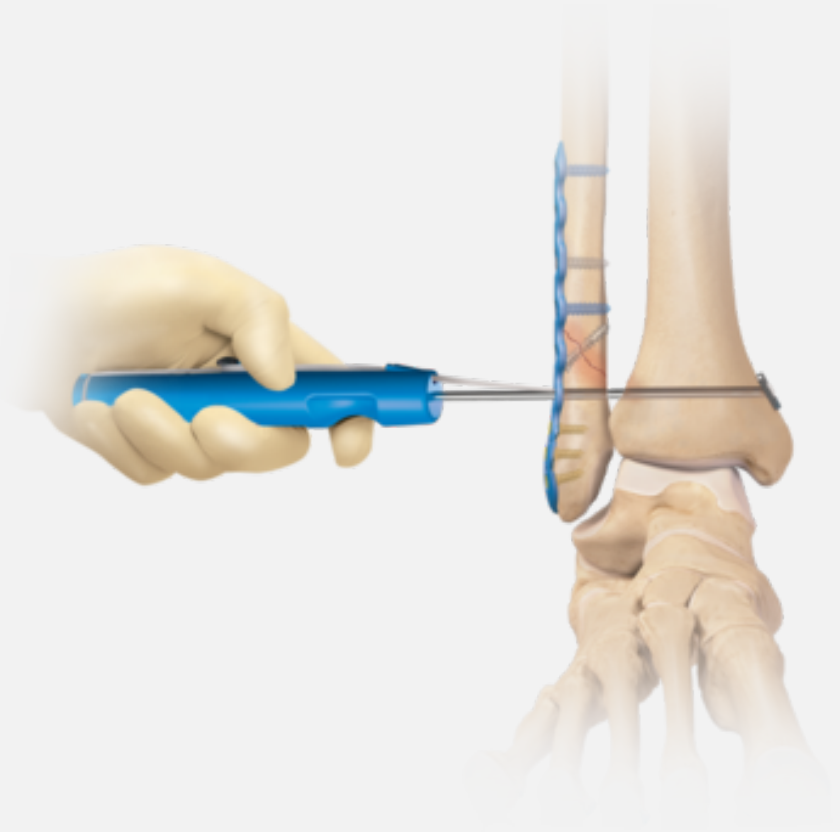

POSTERIOR MALLEOLUS

- USED TO BE 25% RULE
- NOW MORE AGGRESSIVE AS
  - HELPS RESTORE SYNDESOSIS
  - HELPS RESTOORE TIB/FIB JOINT
  - HELP RESTORE POSTERIOR PLAFOND
- PL OR PM APPROACH
- PRONE OR SEMI PRONE
- SCREWS OR ANTIGLIDE

REHAB

NON OP

- WB CAST OR BOOT 6 WEEKS. EARLY ROM

OP

- PLASTER 2 WEEKS
- COMMENCE ROM AT 2 WEEKS
- EITHER PWB OR FWB IN BOOT AT 2-6 WEEKS.
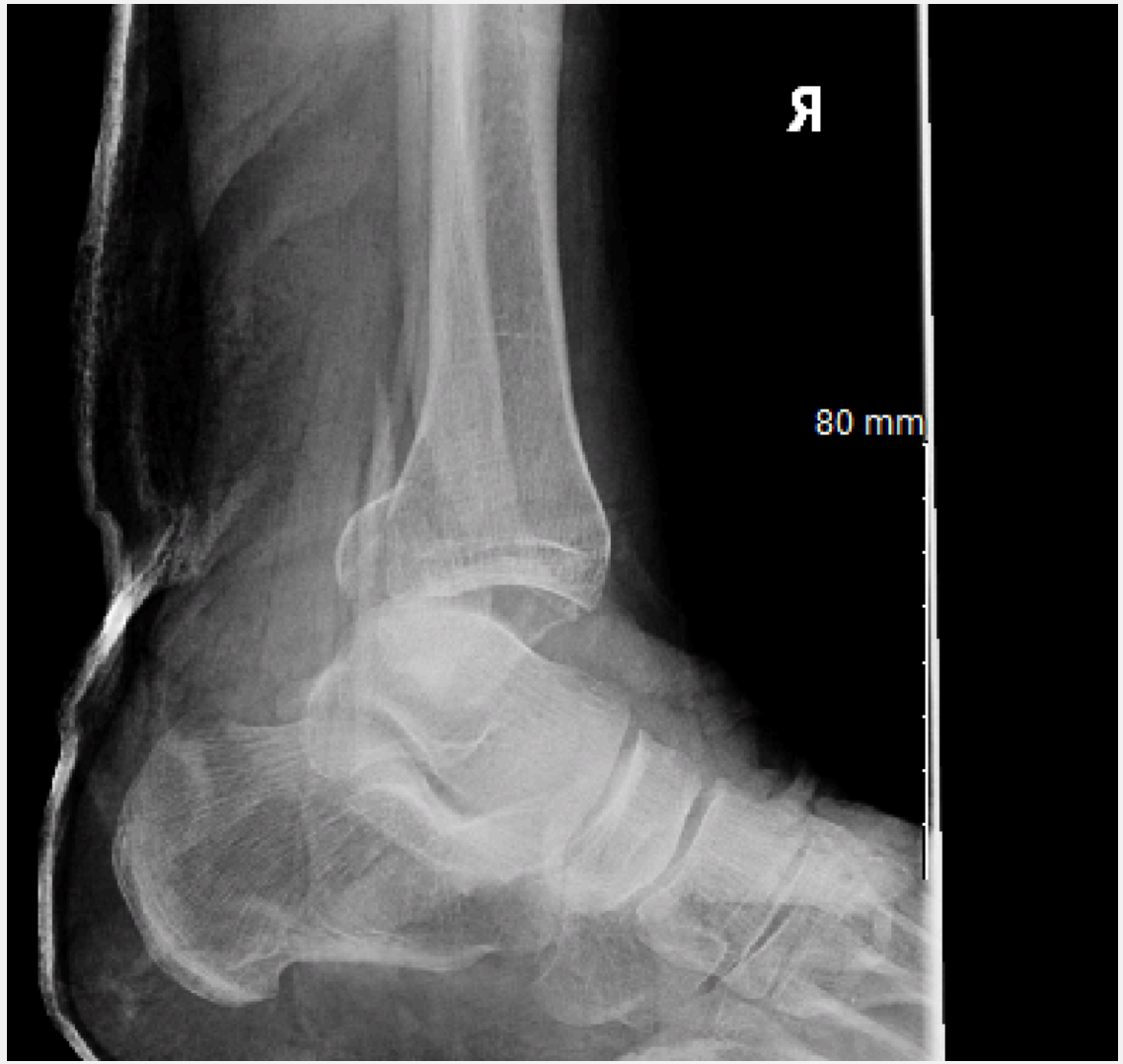
CASE